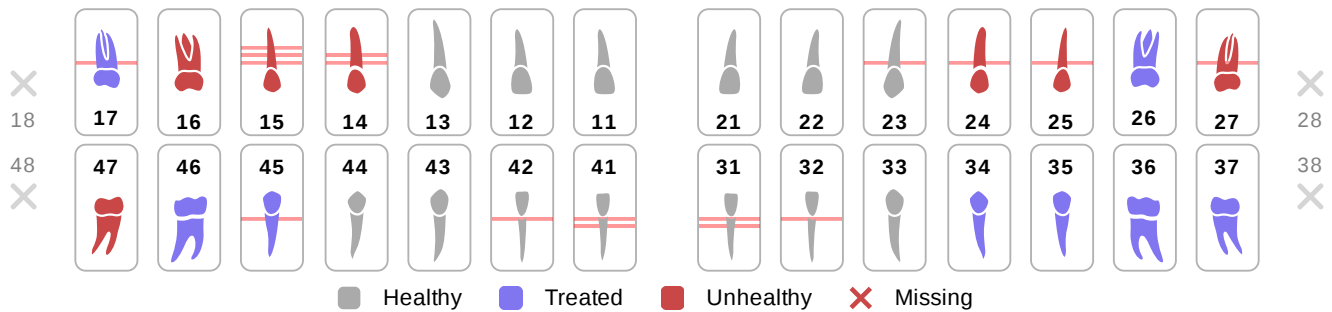
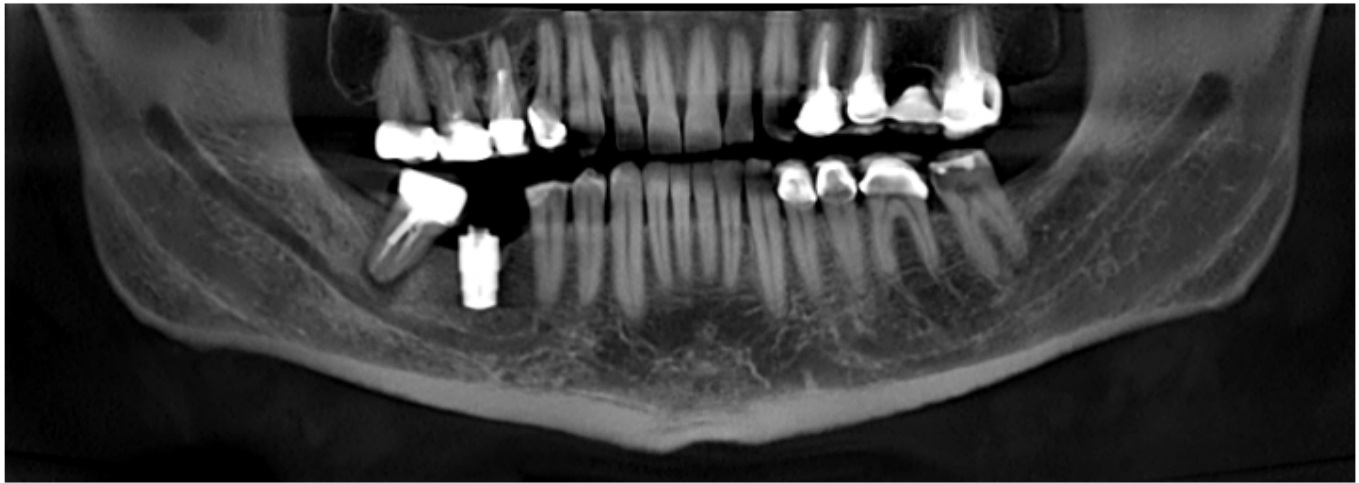

Radiological Report: Teeth 17 — 47
10.05.2021

Patient name: Demo Demo
Date of birth: 01/05/1965

Patient ID: DEMO ID 001245
Scan date: 10/05/2021

Age: 56
Gender: Male



Referral recommendations:

Periodontist: 23, 41, 24, 17, 15, 27, 45, 32, 14, 25, 31, 42 Endodontist: 47, 16, 24, 15, 27, 14, 25

Orthodontic screening

Dental discrepancies

Teeth crowding: 47-46, 45-44, 44-43, 43-42, 42-41, 41-31, 31-32, 17-16, 16-15, 15-14, 12-11, 24-25, 25-26

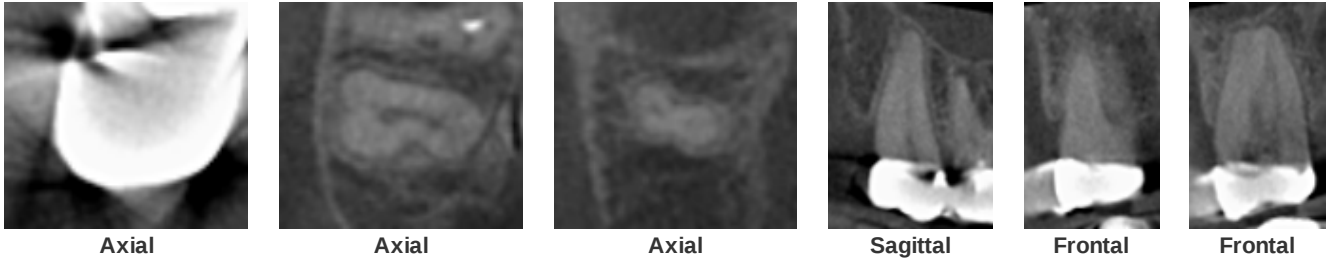
Teeth spacing: 46-45, 22-23

Overbite: decreased

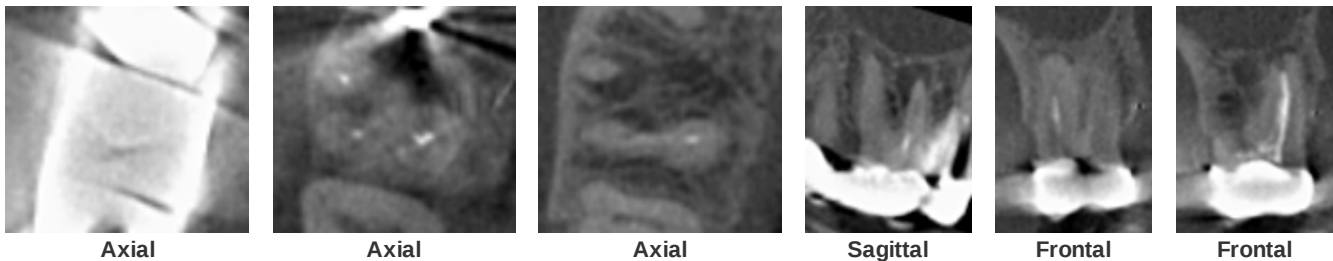
Skeletal discrepancies

No discrepancies found

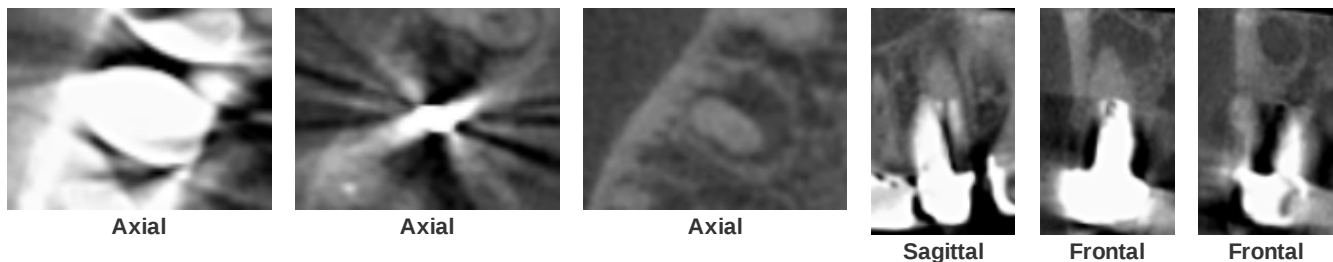
Tooth 17 2 roots, 2 canals, **Periodontal bone loss, mild**, **Artificial crown**.



Tooth 16
3 roots, 3 canals, **Artificial crown**, **Endodontically treated tooth**, **Missed canal**, **Short filling**,
Voids in the root canal filling, **Well circumscribed periapical radiolucency**, **PDL space widening along root**.

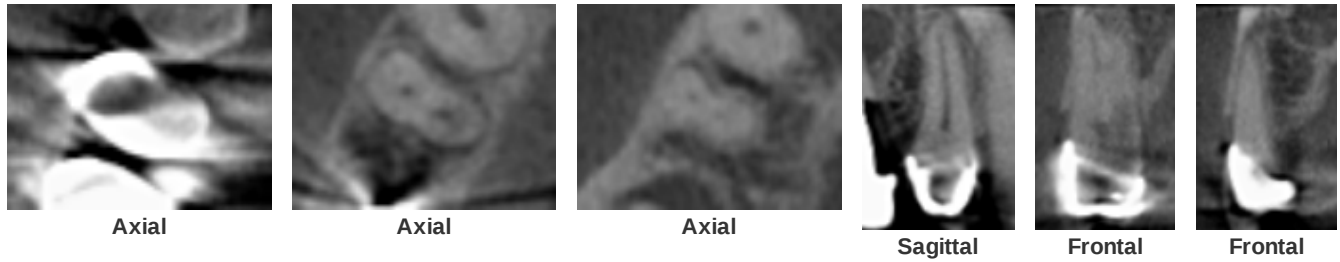


Tooth 15
1 root, 1 canal, **Periodontal bone loss, severe**, **Artificial crown**, **Endodontically treated tooth**, **Short filling**,
Voids in the root canal filling, **Cast Post and Core**, **Well circumscribed periapical radiolucency**,
PDL space widening along root.

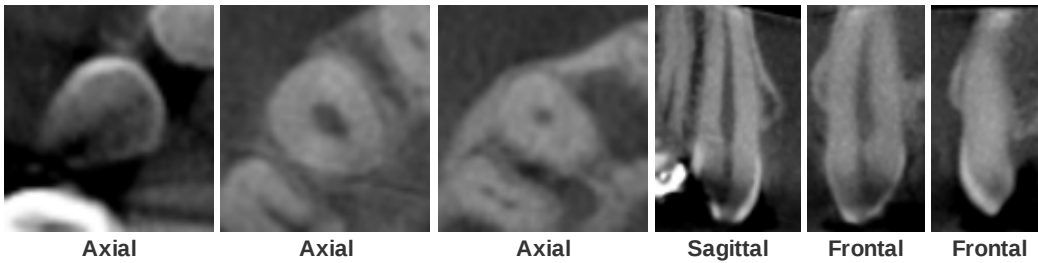


Tooth 14

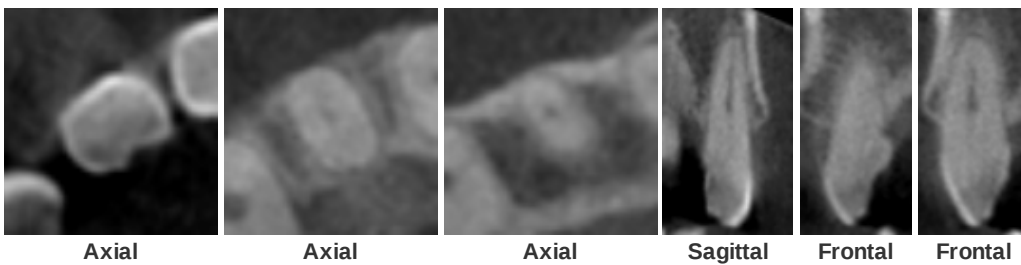
1 root, 2 canals, Periodontal bone loss, moderate, Artificial crown, PDL space widening in periapical region.



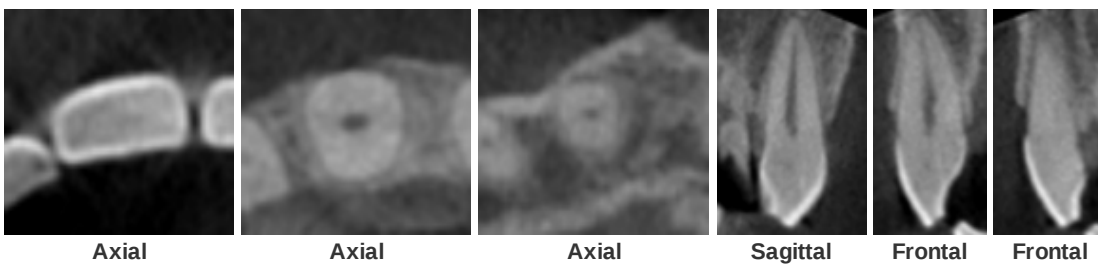
Tooth 13 1 root, 1 canal.



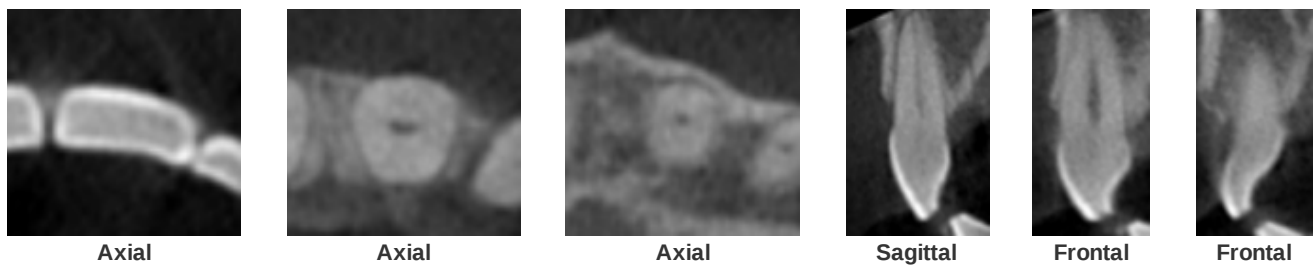
Tooth 12 1 root, 1 canal.



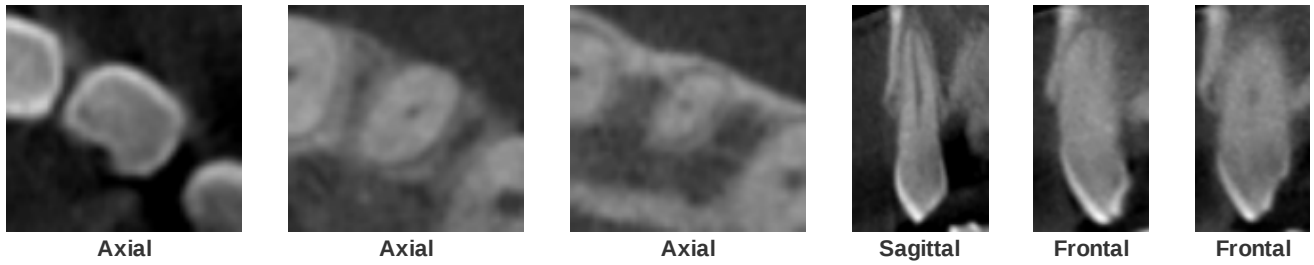
Tooth 11 1 root, 1 canal.



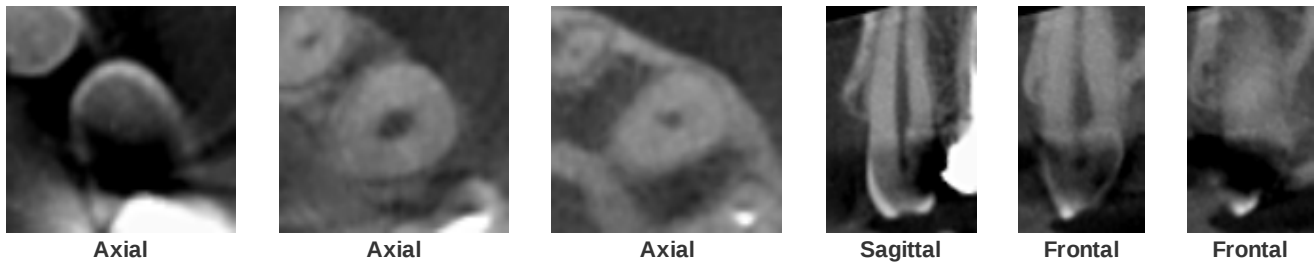
Tooth 21 1 root, 1 canal.



Tooth 22 1 root, 1 canal.

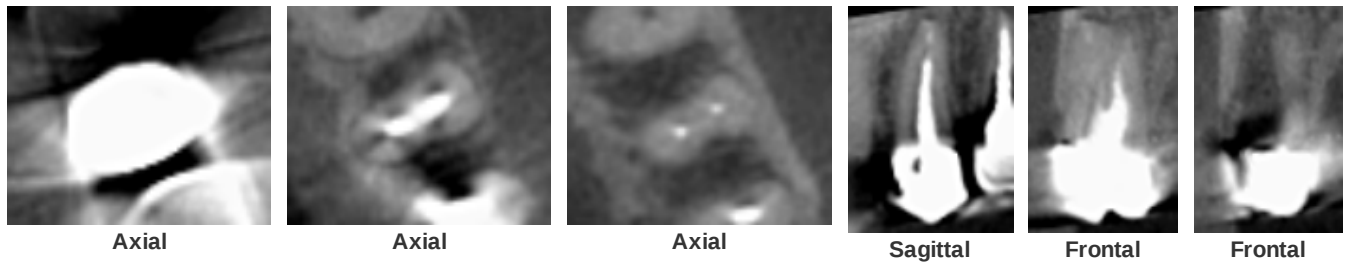


Tooth 23 1 root, 1 canal, **Periodontal bone loss, mild.**



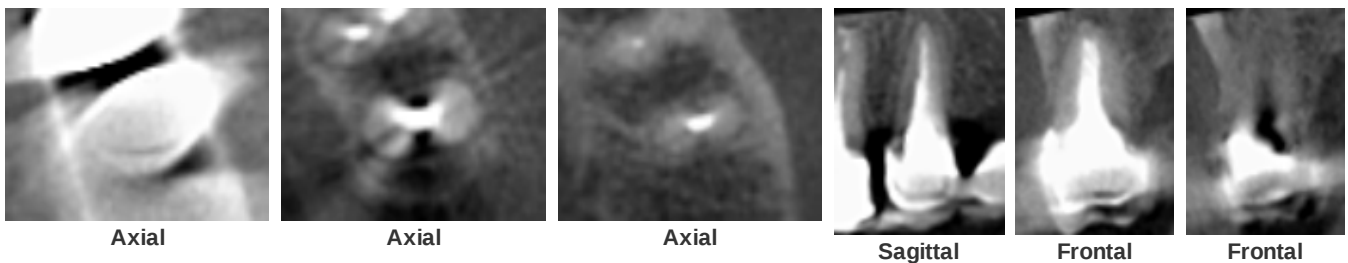
Tooth 24

1 root, 2 canals, **Periodontal bone loss, mild**, **Artificial crown**, **Endodontically treated tooth**, **Short filling**, **Voids in the root canal filling**, **Cast Post and Core**, **PDL space widening in periapical region.**

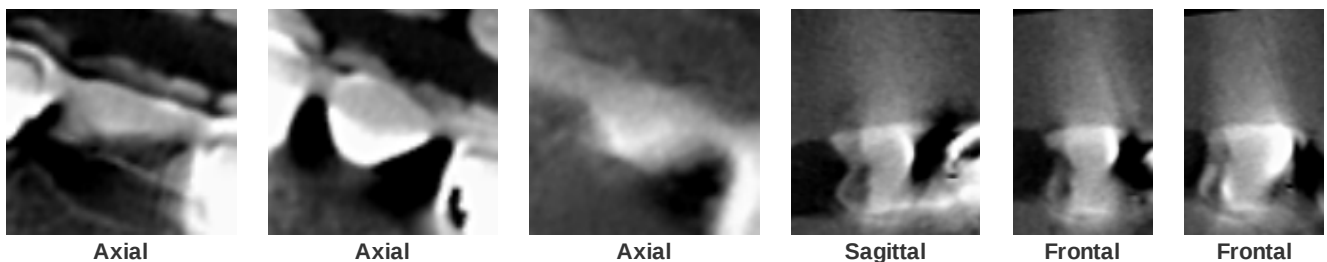


Tooth 25

1 root, 1 canal, **Periodontal bone loss, mild**, **Artificial crown**, **Endodontically treated tooth**, **Adequate obturation**, **Adequate density**, **Cast Post and Core**, **Well circumscribed periapical radiolucency.**

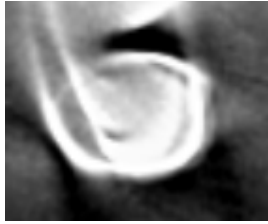

Tooth 26 Pontic.

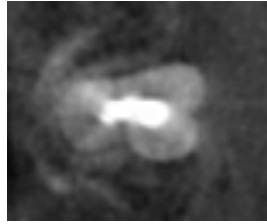


Tooth 27

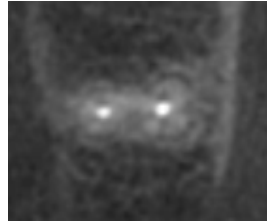
2 roots, 2 canals, **Periodontal bone loss, mild**, **Artificial crown**, **Endodontically treated tooth**, **Adequate obturation**, **Adequate density**, **Cast Post and Core**, **PDL space widening in periapical region**.



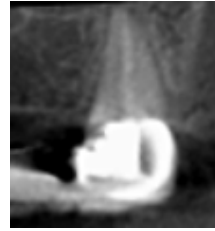Axial



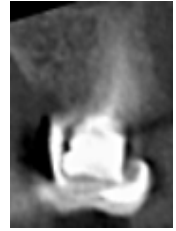Axial



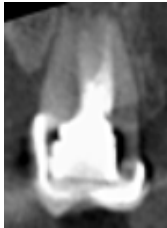Axial



Sagittal

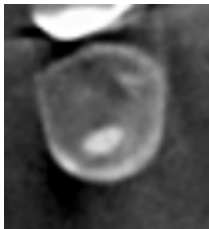

Frontal

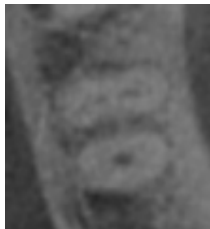

Frontal

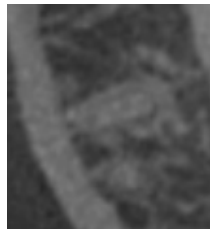
Tooth 37 2 roots, 3 canals, **Filling**.



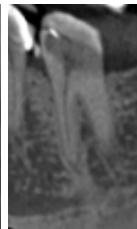
Axial



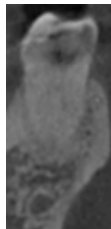
Axial



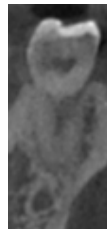
Axial



Sagittal

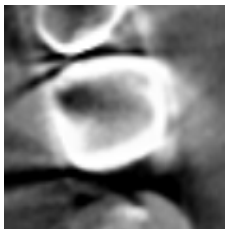


Frontal

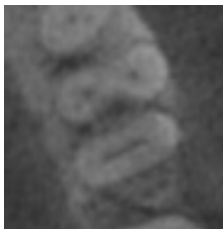

Frontal

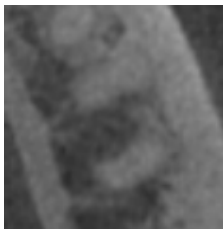Tooth 36 2 roots, 3 canals, **Artificial crown**.



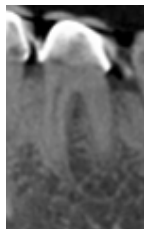
Axial



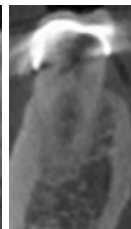
Axial



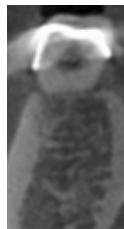Axial



Sagittal



Frontal

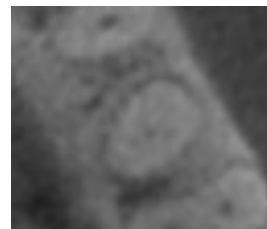

Frontal

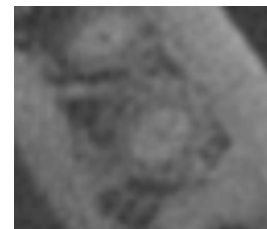Tooth 35 1 root, 1 canal, **Artificial crown**.



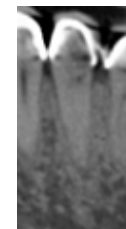
Axial



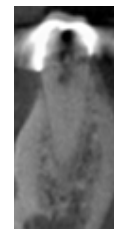Axial



Axial



Sagittal

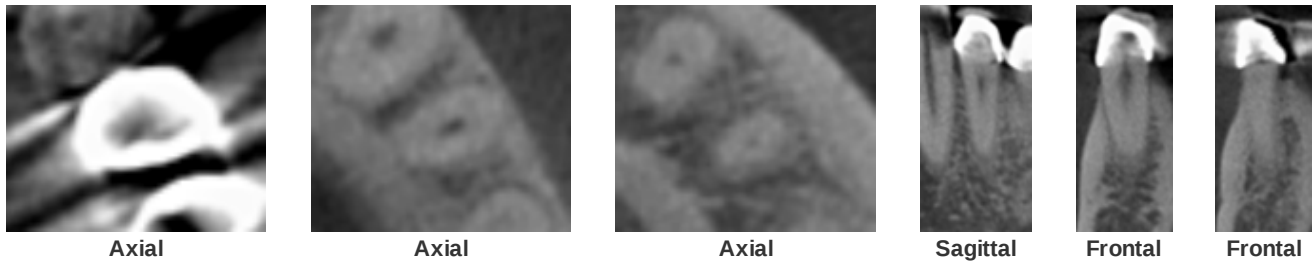


Frontal

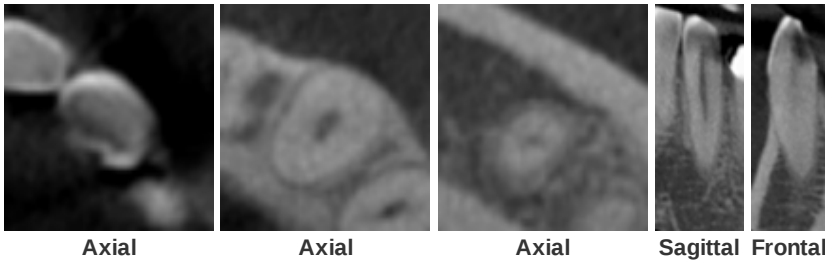


Frontal

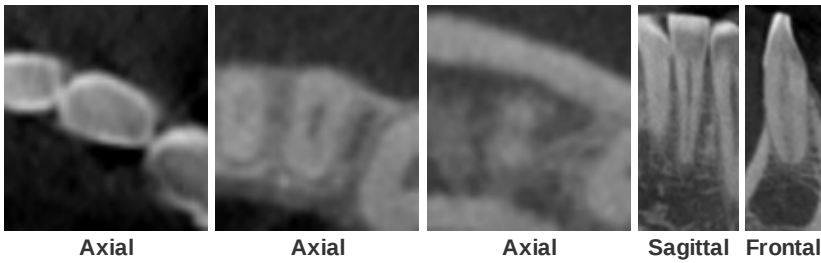
Tooth 34 1 root, 1 canal, **Artificial crown.**



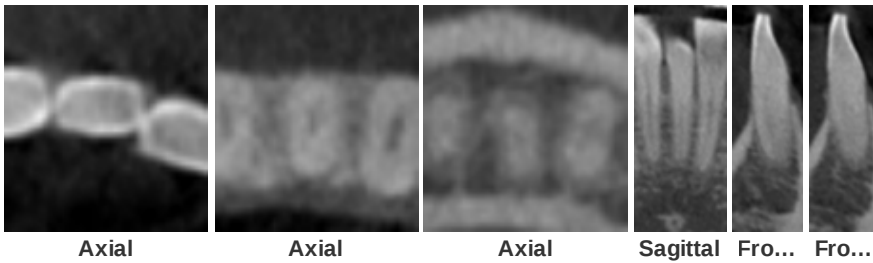
Tooth 33 1 root, 1 canal.



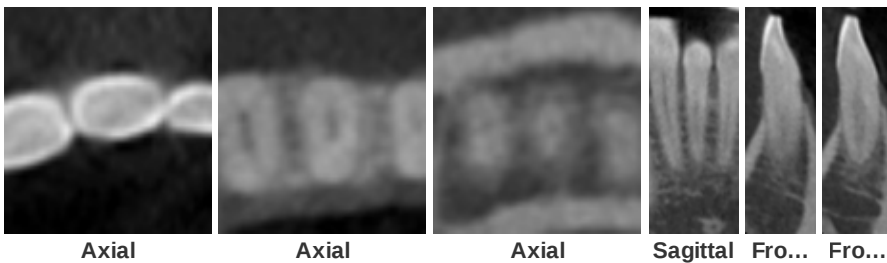
Tooth 32 1 root, 1 canal, **Periodontal bone loss, mild.**



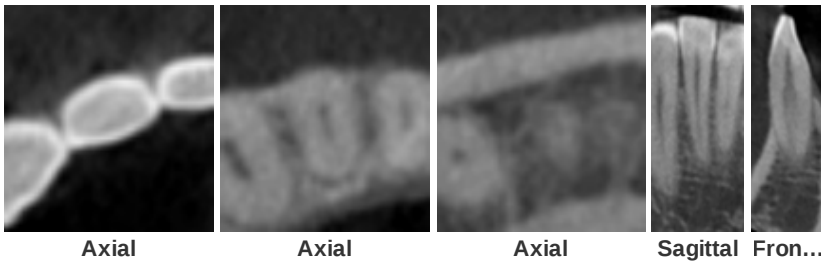
Tooth 31 1 root, 1 canal, **Periodontal bone loss, moderate.**



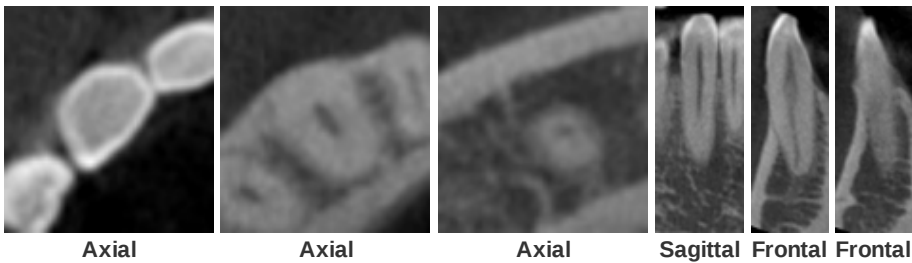
Tooth 41 1 root, 1 canal, **Periodontal bone loss, moderate.**



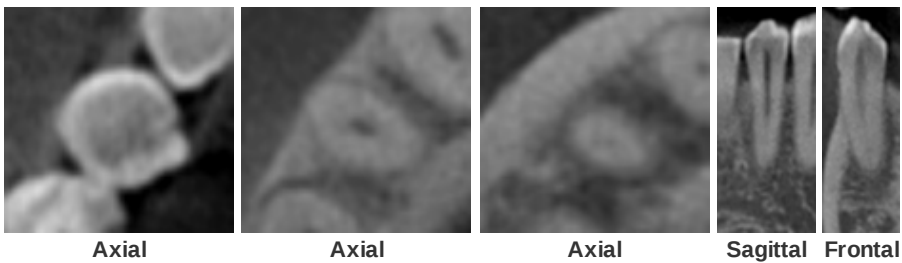
Tooth 42 1 root, 1 canal, **Periodontal bone loss, mild.**



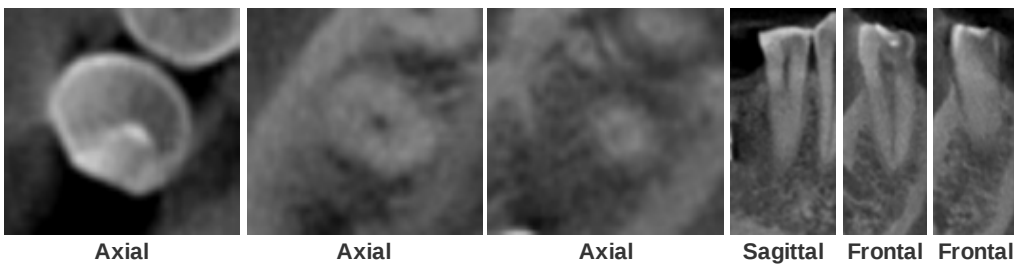
Tooth 43 1 root, 1 canal.



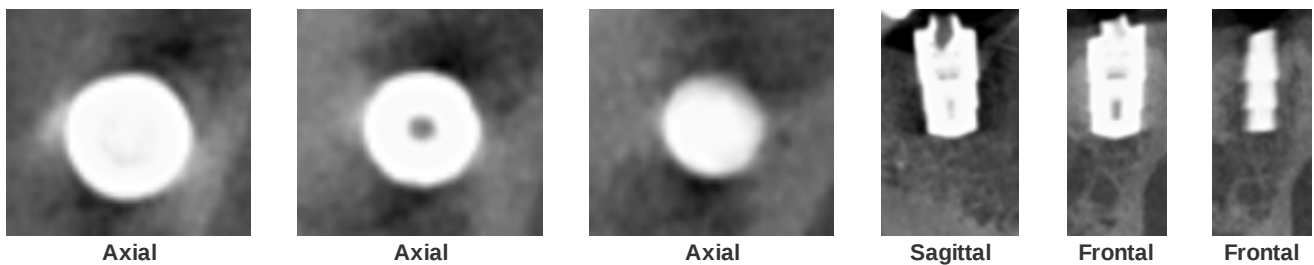
Tooth 44 1 root, 1 canal.



Tooth 45 1 root, 1 canal, **Periodontal bone loss, mild, Filling.**

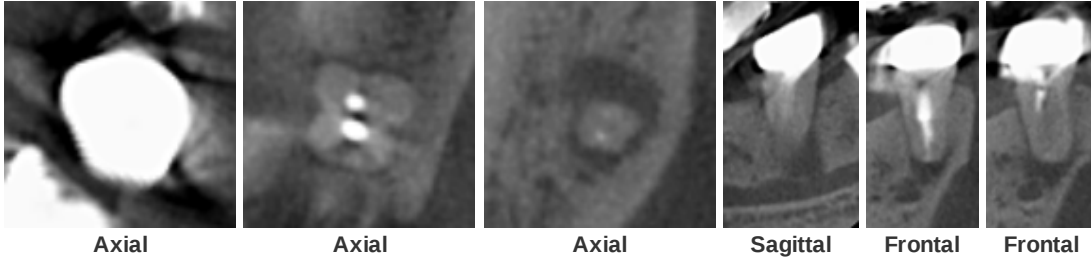


Tooth 46 **Implant.**



Tooth 47

2 roots, 2 canals, Artificial crown, Endodontically treated tooth, Short filling, Voids in the root canal filling, Cast Post and Core, Well circumscribed periapical radiolucency, PDL space widening along root.



Scan info

Manufacturer: Imaging Sciences International

Model: 17-19

Exposure: –

Field of view: 4096 cm³

Voxel: 0.25×0.25×0.25 mm³